

非返性喉返神经的术前诊断及术中损伤的预防

邹 贤, 朱国华, 孙志强, 王国瑞

江苏省原子医学研究所附属江原医院普外科, 无锡市甲状腺病研究所, 江苏 无锡 214063

[摘要] **背景与目的:** 非返性喉返神经是喉返神经罕见的解剖变异, 容易导致甲状腺术中喉返神经的损伤。该研究总结非返性喉返神经的术前诊断和术中损伤预防的经验。**方法:** 回顾性分析11例存在非返性喉返神经患者的临床资料, 结合文献, 探讨非返性喉返神经的术前诊断方法和术中注意事项。**结果:** 术中证实11例均为1型非返性喉返神经, 其中7例术前CT提示存在气管食管后锁骨下动脉, 1例术中切断后行端端吻合。**结论:** 非返性喉返神经是罕见的解剖变异, 术前CT检查可提前判断非返性喉返神经的存在, 术中采用精细化被膜操作技术, 可减少神经损伤的发生。

[关键词] 甲状腺切除术; 喉返神经; 非返性喉返神经

DOI: 10.3969/j.issn.1007-3969.2016.01.017

中图分类号: R736.1 文献标志码: A 文章编号: 1007-3639(2016)01-0107-05

Preoperative prediction and intraoperative injury prevention of nonrecurrent laryngeal nerve ZOU Xian, ZHU Guohua, SUN Zhiqiang, WANG Guorui (Department of General Surgery, Jiangyuan Hospital Affiliated to Jiangsu Institution of Nuclear Medicine, Wuxi Institution of Thyroid Disease, Wuxi 214063, Jiangsu province, China)

Correspondence to: ZOU Xian E-mail: zouxian197825@163.com

[Abstract] **Background and purpose:** A non-recurrent course is a rare anatomic variation of the recurrent laryngeal nerve, which is highly predisposed to injury in thyroidectomy. The study was to summarize preoperative judgment and injury prevention of non-recurrent laryngeal nerve (NRLN) during thyroidectomy. **Methods:** Preoperative diagnosis and precautions during thyroidectomy were investigated, clinical data from eleven cases of NRLN were analyzed and related literature was reviewed as well. **Results:** All eleven cases were NRLN of type 1. Among those, the right subclavian artery was found posteriorly to the trachea and esophagus shown by preoperative CT in seven cases. One case who had NRLN injury underwent nerve anastomosis. **Conclusion:** NRLN is a rare anatomical variation. Preoperative neck CT scan identifies presence of a NRLN, which may reduce the incidence of nerve injuries by using intraoperative capsular dissection.

[Key words] Thyroidectomy; Recurrent laryngeal nerve; Non-recurrent laryngeal nerve

喉返神经损伤是甲状腺手术的重要并发症之一, 会导致患者术后声音嘶哑, 甚至可引起窒息危及生命。非返性喉返神经(non-recurrent laryngeal nerve, NRLN)为临床上罕见的解剖变异, 缺乏对于NRLN的了解, 术中容易导致其损伤。本研究回顾性分析了江苏省原子医学研究所附属江原医院11例NRLN患者的资料, 结合文献探讨NRLN术前的诊断及术中的保护技巧。

1 资料和方法

1.1 一般资料

江苏省原子医学研究所附属江原医院2013年1月—2013年12月共行甲状腺手术1 602例, 术中常规行手术侧的喉返神经探查, 探测左侧喉返神经1 085根, 探测右侧喉返神经1 123根, 其中11例患者为NRLN, 均为右侧, NRLN发生率占总手术病例的0.68%。11例患者均为初治患者, 既

表 1 11例非返性喉返神经患者的临床资料

Tab. 1 Clinical characteristics of eleven patients with NRLN

Number	Gender	Age/year	Approach of operation	Pathology
1	Male	27	Total thyroidectomy	Nodular goiter
2	Male	59	Total thyroidectomy	Nodular goiter
3	Female	58	Total thyroidectomy plus bilateral central compartment lymph node dissection	Papillary carcinoma on the isthmus
4	Male	40	Right thyroidectomy plus right central compartment lymph node dissection	Papillary carcinoma on the right lobe
5	Female	55	Total thyroidectomy	Nodular goiter
6	Male	59	Right thyroidectomy	Nodular goiter
7	Male	54	Total thyroidectomy plus right central compartment lymph node dissection	Papillary carcinoma on the right lobe
8	Male	60	Total thyroidectomy plus left central compartment lymph node dissection	Papillary carcinoma on the left lobe
9	Female	24	Right thyroidectomy	Nodular goiter
10	Female	45	Total thyroidectomy plus bilateral central compartment lymph node dissection	Papillary carcinoma on the bilateral lobe
11	Female	71	Total thyroidectomy plus left central compartment lymph node dissection	Papillary carcinoma on the left lobe

往无颈部及胸部手术史(表1)。

7例NRLN患者术前曾行颈部CT检查(平扫+增强), CT检查为下颌骨平面至气管隆突平面, 扫描层厚3 mm。CT均提示右侧头臂干缺如, 右锁骨下动脉由主动脉弓的背侧分出, 经食管和气管的后方向右侧腋下区域延伸(图1)。多层面重建(multiplanar reconstruction, MPR)和三维CT血管造影(three-dimensional computerized tomography angiography, 3D-CTA)进一步证实这种解剖变异的存在(图2)。

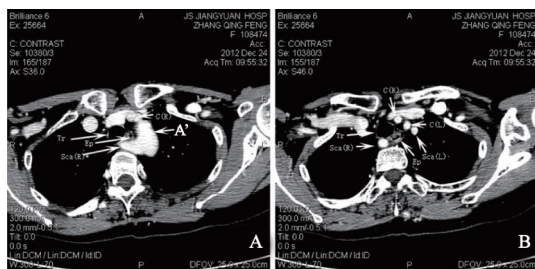


图 1 NRLN的CT平面成像特征

Fig. 1 The CT planar imaging features of NRLN

A: The right subclavian artery came from the dorsal side of the aortic arch, passed through the posterior of the trachea and esophagus, and showed the “hook-like” morphology; B: The right subclavian artery could be observed behind the trachea and esophagus; Tr: Trachea; Sca: Subclavian artery; EP: Esophagus; C: Common carotid artery; A': Aortic arch; R: Right; L: Left

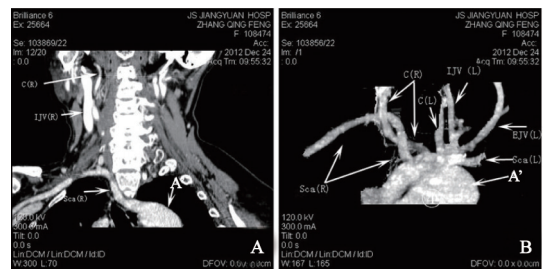

图 2 NRLN的MPR和3D-CTA特点

Fig. 2 The MPR and 3D-CTA features of NRLN

A: The MPR showed that, after issued from the aortic arch, the right subclavian artery traveled to the right subaxillary region, did not intersect with the right common carotid artery; B: 3D-CTA showed the brachiocephalic trunk absent, the right subclavian artery and right common carotid artery were originated from the aortic arch respectively. Sca: Subclavian artery; C: Common carotid artery; EJV: External jugular vein; IJV: Internal jugular vein; A': Aortic arch; R: Right; L: Left

1.2 术中喉下神经的探查方法

首先游离甲状腺外侧, 切断、结扎甲状腺中静脉后, 切断、结扎甲状腺上极血管, 完全暴露甲状腺后包膜。开始以Simon三角(甲状腺下动脉、喉返神经及颈内动脉组成的三角)定位原则探查喉下神经, 如能探及银白色条索状结构沿气管食管沟上行, 至咽下缩肌下缘入喉点入喉, 则该条索状结构为喉返神经; 如在气管食

管沟内未探及喉返神经，自入喉点向颈动脉鞘方向探查，发现有银白色条索状结构，其近端为迷走神经，则该索条状结构为NRLN。

2 结 果

本研究中的11例患者术中均证实为NRLN，喉返神经均起源于甲状腺上极高度的迷走神经，下行沿环甲肌的下缘入喉(图3)。上述11例中，10例术后未出现声音嘶哑和呼吸困难；1例因术者用直角血管钳处理甲状腺上极时离入喉点过近，导致NRLN连同甲状腺上极血管和结缔组织一起被切断，术中发现后即予以NRLN端端吻合，术后出现声音嘶哑，喉镜检查提示右侧声带麻痹，静脉滴注甲基泼尼松龙3 d，出院后口服甲钴胺营养神经治疗，半年后患者声音嘶哑症状明显改善。采用喉镜复查提示，右侧声带麻痹，左侧声带代偿，声门闭合良好。

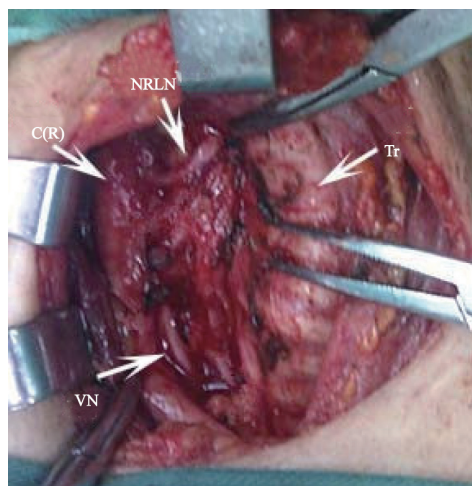


图3 NRLN术中图片

Fig. 3 Intraoperative photograph of NRLN

C(R): Right common carotid artery; VN: Nervus vagus; Tr: Trachea

3 讨 论

正常的喉返神经为胸段迷走神经的分支，左侧勾绕主动脉弓，右侧勾绕锁骨下动脉，均沿气管食管沟上行，至咽下缩肌下缘、环甲关节入喉。NRLN是其罕见的变异类型，它由颈段迷走神经发出分支直接入喉。相关报道统计右侧NRLN发生率为0.32%~0.79%，左侧NRLN

发生率小于0.07%^[1-4]。出现NRLN的原因与胚胎期第6对弓动脉的发育有密切关系。正常的胚胎发育过程中，当心脏下降时，双侧喉返神经绕第6对鳃弓动脉下方上行，最后入喉。随着右侧第5、6对鳃弓动脉消失，左侧第6对鳃弓动脉残留为动脉韧带，最后只剩下第4对鳃弓动脉，分别演变为右侧锁骨下动脉的开始部分和主动脉弓的一部分。因此双侧喉返神经分别绕右锁骨下动脉和动脉韧带左侧的主动脉弓上行，最终入喉。如果胚胎发育过程中，第4对鳃弓动脉消失，右侧锁骨下动脉则由右侧背侧主动脉演变，从左侧的主动脉弓发出，经过食管后右行通向腋窝。这种解剖变异导致右侧的喉返神经无法勾绕正常位置的右锁骨下动脉，而由颈部的迷走神经直接横行入喉，形成了右侧NRLN^[5]。而形成左侧NRLN，则需满足以下条件：①右位主动脉弓，并同时存在内脏逆位；②左侧锁骨下动脉沿食管后途径走行；③动脉韧带位于右侧。如果动脉韧带位于左侧，则左侧喉返神经仍然会勾绕，形成返性喉返神经^[6-8]。另有一些学者所报道的同时存在返支和非返支的喉返神经，以及没有血管的变异，而存在的右侧NRLN，目前尚无法从胚胎学的角度去解释^[6-11]。

对于NRLN的分型目前无统一的标准。国内李新营等^[6]将其分为4型：I型，完全性右侧NRLN；II型，完全性左侧NRLN；III型，同时具有返支和非返支的右侧NRLN；IV型，同时具有返支和非返支的左侧NRLN。国外学者根据NRLN从迷走神经分出的高度以及行走的路径，将喉NRLN分3型：NRLN 1型为NRLN在喉与气管连接处的迷走神经分出，与甲状腺下动脉伴行直接入喉；NRLN 2A型为NRLN在相当于甲状腺峡部平面自迷走神经分出，行走于甲状腺下动脉的上方，上行入喉；NRLN 2B型为NRLN在相当于甲状腺峡部平面自迷走神经分出，先向下行走，绕过甲状腺下动脉后上行入喉^[13](图4)。我们认为后者的分型方法更具有临床价值。本研究也采用这种分型方法，所有患者均为NRLN 1型。

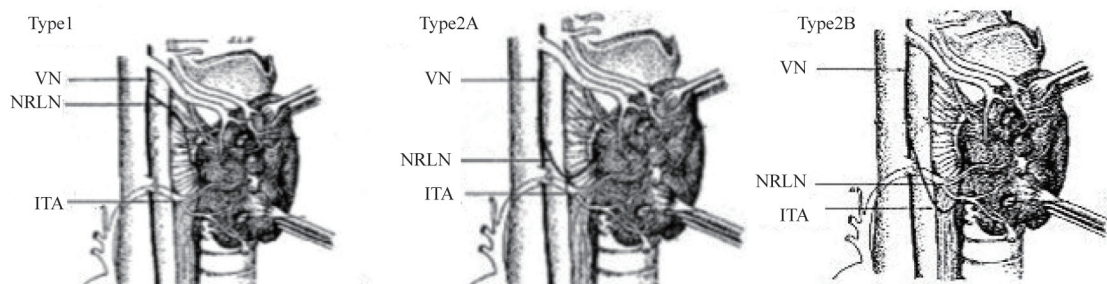


图4 NRLN分型

Fig. 4 Types of NRLN

VN:Nervus vagus; ITA: Inferior thyroid artery

NRLN本身无特异性的临床症状。但考虑到这种解剖变异的成因中有血管畸形或内脏逆位存在,可以通过CT、MRI以及B超等影像特征来提前预知。国内外许多学者对于NRLN的术前CT诊断做了大量的研究,归纳出符合右侧NRLN的CT特征:①右侧头臂干缺失;②右侧锁骨下动脉起源于主动脉弓的背侧,经食管、气管后方向右腋行走,形成钩状形态;③右锁骨下直接自主动脉弓发出,于右颈总动脉后方行走^[14-16]。本研究中有5例患者术前CT与上述CT特征吻合,术中证实为右侧NRLN。而对于术前CT提示有主动脉弓反位和内脏逆位,以及可疑食管气管后左锁骨下动脉的患者,术中需考虑左侧NRLN的可能性。另有一些学者术前行MRI或超声波的检查,根据影像所提示头臂干的缺如和食管后的锁骨下动脉,也能明确NRLN的存在^[17-18]。

术前仔细分析CT等影像学检查结果,提前判断是否有NRLN存在的可能性,但对于所提示的正常影像,也要警惕有NRLN的可能,既往已有多篇关于存在NRLN但无解剖变异的报道^[2, 11-12]。对于行甲状腺腺叶切除、甲状腺腺叶近全切除,以及肿块位于后包膜的甲状腺部分切除,术中需常规暴露喉下神经以降低喉下神经误伤的发生率。术中需注意如下几点:①当在正常位置未探及喉返神经时,需警惕NRLN的可能性;在未明确喉返神经前,盲目地切断甲状腺与颈动脉鞘之间横行的条索状结构,易导致2型NRLN的损伤。②甲状腺上极距

离入喉点位置近,所以在处理甲状腺上极时,需紧贴甲状腺对血管分支仔细辨别与结扎,有利于避免1型NRLN的损伤。③术前CT诊断结果提示有NRLN的存在,术中也应首先探及NRLN,术者在切除甲状腺前,仍需仔细解剖喉返神经的常规路径,以明确是否同时存在喉返神经返支;若探查至食管气管沟内的喉返神经十分纤细,也需考虑到喉返神经非返支同时存在的可能性。④精细化被膜操作技术除了能有效保护甲状旁腺之外,还能降低术中喉返神经损伤的发生率^[19-20]。⑤对于二次手术黏连严重者,且术前CT诊断结果提示有右侧头臂干的缺如、存在右侧食管后的锁骨下动脉,可首先打开颈动脉鞘,显露迷走神经来探查NRLN的位置。⑥术中神经监测如果在甲状腺下极水平未探及迷走神经肌电信号,而在甲状腺上极水平探及迷走神经信号,则需考虑存在NRLN。术中应加以保护NRLN,可降低其损伤的发生率^[14,21]。

由于NRLN的存在,增加了术中喉返神经损伤的风险。术者必须熟悉喉返神经正常的路径和解剖变异,术前仔细分析相关影像学检查结果,提前判断NRLN的存在,术中精细化操作,降低神经损伤发生的概率。

[参 考 文 献]

- [1] DOCIMO G, AVENIA N, RAGUSA M, et al. Non recurrent inferior laryngeal nerve: our surgical experience [J]. Clin Ter, 2009, 160(5): 347-349
- [2] HENRY J F, AUDIFFRET J, DENIZOT A, et al. The

- nonrecurrent inferior laryngeal nerve: review of 33 cases, including two on the left side [J]. *Surgery*, 1988, 104(6): 977-984.
- [3] PROYE C A, CARNAILLE B M, GOROPULOS A. Nonrecurrent and recurrent inferior laryngeal nerve: a surgical pitfall in cervical exploration [J]. *Am J Surg*, 1991, 162(5): 495-496.
- [4] DEFECHEREUX T, ALBERT V, ALEXANDRE J, et al. The inferior non recurrent laryngeal nerve: a major surgical risk during thyroidectomy [J]. *Acta Chir Belg*, 2000, 100(2): 62-67.
- [5] MOHEBATI A, SHAHA A R. Anatomy of thyroid and parathyroid glands and neurovascular relations [J]. *Clin Anat*, 2012, 25(1): 19-31.
- [6] 李新营, 吕新生, 王志明, 等. 非返性喉返神经损伤的预防 [J]. *中华耳鼻咽喉科杂志*, 2004, 39(7): 415-418.
- [7] BABADEMEZ M A, GÜNBAY E, OZMEN E, et al. Anomalous relationship of coexisting ipsilateral recurrent and nonrecurrent inferior laryngeal nerves during thyroid surgery [J]. *J Craniofac Surg*, 2013, 24(2): e190-e192.
- [8] RAFFAELLI M, LACOBONE M, HENRY J F. The "false" nonrecurrent inferior laryngeal nerve [J]. *Surgery*, 2000, 128(6): 1082-1087.
- [9] TONIATO A, RUBELLO D, MERANTE BOSCHIN I. Nonrecurrent and ipsilateral recurrent inferior laryngeal nerves [J]. *Minerva Chir*, 2012, 67(3): 286-287.
- [10] YANG Y S, NO S K, CHOI S C, et al. Case of coexisting, ipsilateral nonrecurrent and recurrent inferior laryngeal nerves [J]. *J Laryngol Otol*, 2009, 123(07): e17.
- [11] TATEDA M, HASEGAWA J, SAGAI S, et al. Nonrecurrent inferior laryngeal nerve without vascular anomaly as a genuine entity [J]. *Tohoku J Exp Med*, 2008, 216(2): 133-137.
- [12] COADY M A, ADLER F, DALA J J, et al. Nonrecurrent laryngeal nerve during carotid artery surgery: case report and literature review [J]. *J Vasc Surg*, 2000, 32(1): 192-196.
- [13] TONIATO A, MAZZAROTTO R, PIOTTO A, et al. Identification of the nonrecurrent laryngeal nerve during thyroid surgery: 20-year experience [J]. *World J Surg*, 2004, 28(7): 659-661.
- [14] CAI Q, GUAN Z, HUANG X, et al. The usefulness of preoperative computed tomography and intraoperative neuromonitoring identification of the nonrecurrent inferior laryngeal nerve [J]. *Eur Arch Otorhinolaryngol*, 2013, 270(7): 2135-2140.
- [15] WANG Y, JI Q, LI D, et al. Preoperative CT diagnosis of right nonrecurrent inferior laryngeal nerve [J]. *Head Neck*, 2011, 33(2): 232-238.
- [16] LEE Y S, SON E J, CHANG H S, et al. Computed tomography is useful for preoperative identification of nonrecurrent laryngeal nerve in thyroid cancer patients [J]. *Otolaryngol Head Neck Surg*, 2011, 145(2): 204-207.
- [17] MARCHESI M, BIFFONI M, FALOCI C, et al. The inferior nonrecurrent laryngeal nerve: a report of 7 cases observed since 1987 [J]. *G Chir*, 2000, 21(1-2): 25-28.
- [18] IACOBONE M, VIEL G, ZANELLA S, et al. The usefulness of preoperative ultrasonographic identification of nonrecurrent inferior laryngeal nerve in neck surgery [J]. *Langenbecks Arch Surg*, 2008, 393(5): 633-638.
- [19] 高力, 谢磊, 叶学红, 等. 甲状腺全切除或近全切除术治疗 180 例甲状腺癌的手术体会 [J]. *外科理论与实践*, 2003, 8(4): 300-303.
- [20] GOUGH I R, WILKINSON D. Total thyroidectomy for management of thyroid disease [J]. *World J Surg*, 2000, 24(8): 962-965.
- [21] 孙辉. 甲状腺及甲状旁腺手术中神经电生理监测临床指南 (中国版) [J]. *中国实用外科杂志*, 2013, 33(6): 470-474.

(收稿日期: 2015-03-07 修回日期: 2015-09-11)